

RC with ileal conduit lessons to be learned

Badrinath Konety, MD, FACS

President Allina Health Cancer Institute

Chief System Research Officer

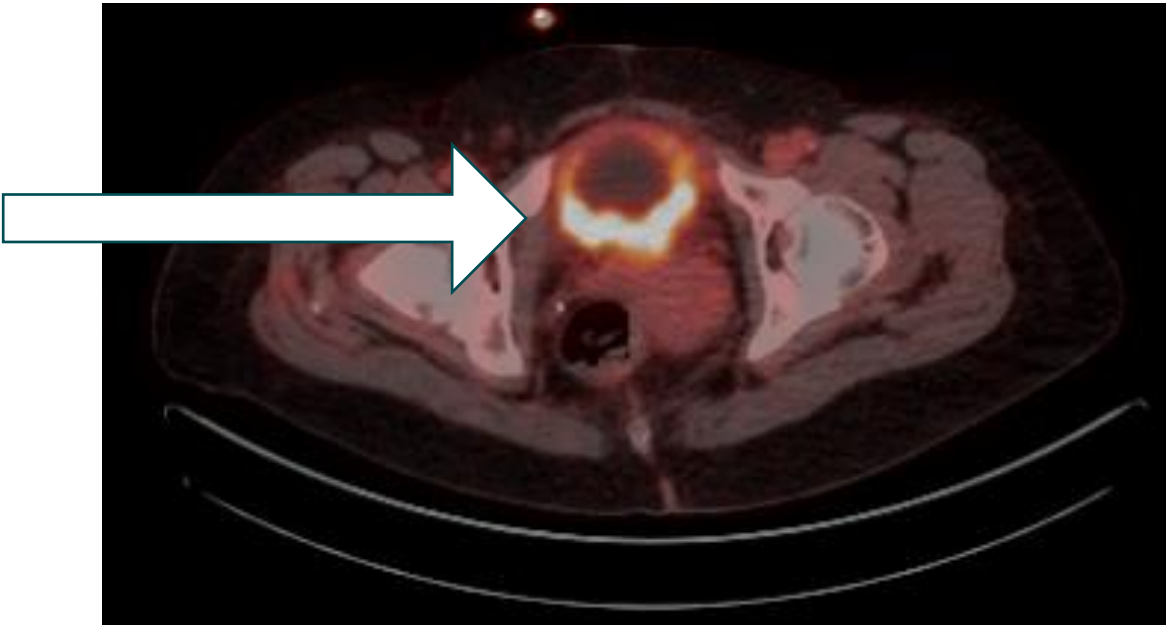
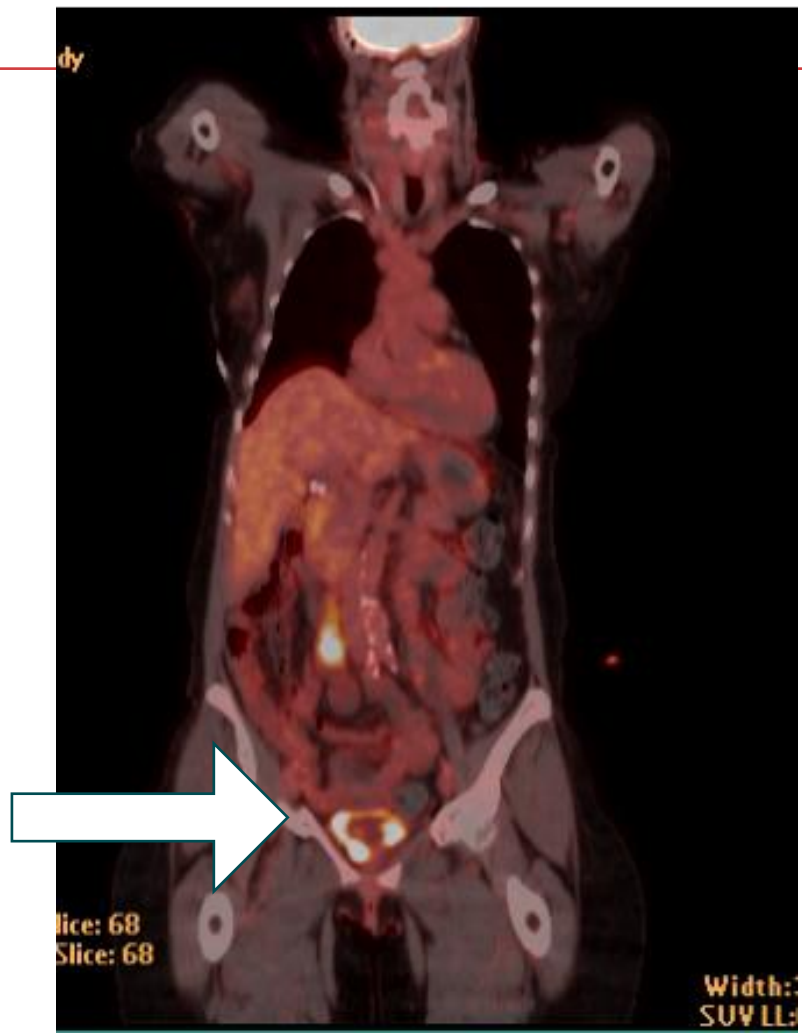


Conflicts of interest

| Type of affiliation / financial interest | Name of commercial company |
|---|--|
| Receipt of grants/research supports | BMS, Photocure, Pacific Edge |
| Receipt of honoraria or consultation fees | Asieris Pharmaceuticals |
| Stock shareholder | Astrin Biosciences, Styx Biotechnologies |
| Other support (please specify): | |

Clinical case #1

- 61 year old lady presented with gross hematuria
- Smoker – 40 pack year history
- No other medical problems.
- Depression on no treatment
- Divorced but in a relationship
- TURB – MIBC urothelial carcinoma with squamous differentiation
- Advised NAC



Question

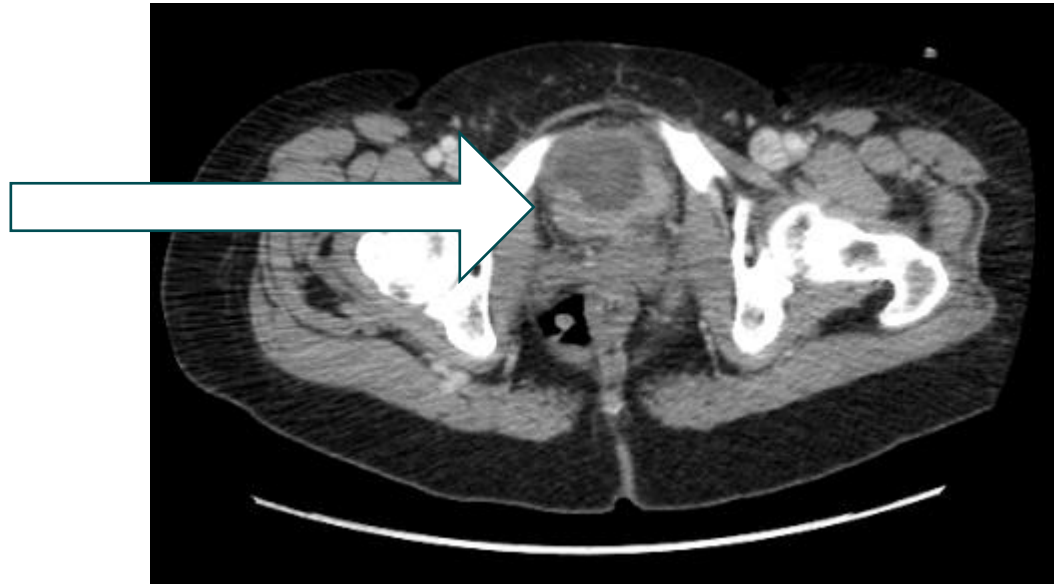- What other evaluation would you perform?
- What advise would you provide for someone undergoing NAC?
- Are there opportunities for prehabilitation in this patient?
- Is the baseline depression a concern?
- How do you help this patient prepare for life changing surgery?
- How do we prepare the family?

Chemo course

- Bilateral hydronephrosis – best management
- Issues with chemo – logistics, pain, preparation etc.
- Conditioning during chemo

- This lady developed bilateral pulmonary emboli during chemo
 - Management
 - Implications for surgery
 - Limitations on activity and how to cope with prehab?

Post chemo CT scan

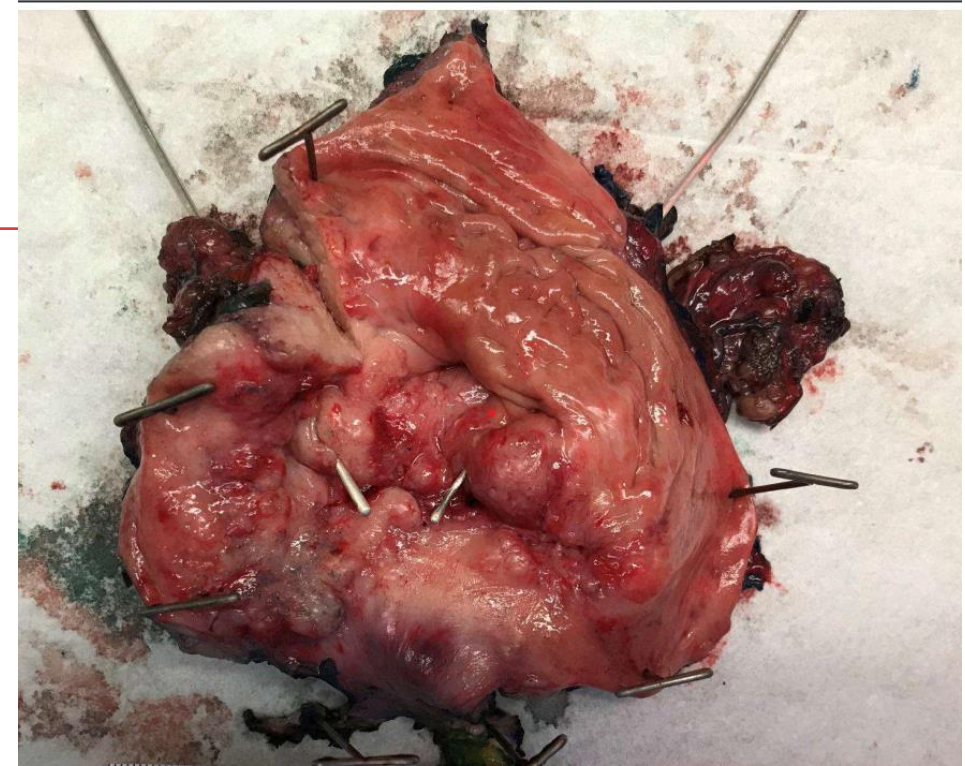

Surgical considerations

- Very interested in maintaining normal body image
- Maintenance of sexual function very important
- Options for diversion?

Cystectomy findings

- Locally extensive disease pT4aN2Mx
 - Gyn organ sparing not feasible
 - Urethral margin positive
 - Ileal conduit performed
-
- Significant post operative issues with stoma appliance fit and self management



Question

- How do you teach patients stoma management and to overcome issues with self management?
- What rehabilitation measures should be undertaken in women to maximize restoration of sexual function?